

CME Article

Radiographical approach to jaw lesions

Neyaz Z, Gadodia A, Gamanagatti S, Mukhopadhyay S

ABSTRACT

Many lesions that occur in the jaw have a similar radiographical appearance and it is often difficult to differentiate among them. Despite development of various cross-sectional imaging modalities, the radiograph still remains the first and the most important investigation. Radiographical evaluation of jaw lesion characteristics, which include location, margin, density, relation to tooth, along with knowledge of the clinical data, generally helps in narrowing the differential diagnosis.

Keywords: dental lesion, jaw lesion, maxillary lesion, mandible lesion, radiography

Singapore Med J 2008; 49(2): 165-177

INTRODUCTION

Even after development of many modern imaging modalities, radiography still remains the most important mode of investigation for the evaluation of jaw lesions. Intraoral radiographs offer a highly detailed view of the teeth and bone in the area exposed, but it cannot be used for lesions larger than 3 cm, because of the small film size. Extraoral radiographs are used to examine larger lesions and to visualise the skull and facial structures. Panoramic radiography is a special technique, which includes a broad area with low radiation dose, and it can be used in patients who are unable to open their mouths.^(1,2) Although the whole spectrum of jaw lesions is beyond the scope of this article, we have presented the characteristic imaging findings of commonly-encountered jaw lesions.

Jaw lesions are difficult to distinguish from each other on radiography. The patient's history and an analytical approach to radiographs help in narrowing down the differential diagnosis. Any jaw lesion should be evaluated taking into consideration the following radiological features:^(3,4)

Density of lesion, margin, locularity

Jaw lesions can be described as having either a radiolucent, radiopaque, or mixed appearance, relative to density of the adjacent bone (Table I). The majority of jaw lesions are radiolucent (> 80%). Unilocular radiolucent lesions with well-defined borders usually indicate a slow proliferating benign process. Multilocular lesions with well-defined borders indicate a benign yet aggressive process. Radiopaque lesions which are well-defined, usually represent a benign or inflammatory aetiology. In general, lesions with well-defined borders are usually benign, whereas lesions with ill-defined

borders invariably represent aggressive, inflammatory or neoplastic processes. Mixed radiolucent-radiopaque lesions can be due to inflammatory, metabolic conditions, fibro-osseous lesions, or less commonly, malignant processes.

Anatomical location, relation to dentition

Certain lesions have a predilection for a particular site, whereas others can occur anywhere in the jaw (Table II). Non-odontogenic lesions usually have no specific relationship to the dentition or can involve the bone around two or more teeth, whereas odontogenic lesions typically involve only one tooth or a specific part of the tooth. Relationship of the lesion with respect to the inferior alveolar canal indicates tissue types that compose the lesion. Lesions above the canal are likely to be odontogenic, whereas lesions below it are usually non-odontogenic in nature. If the abnormal appearance affects all the structure of maxillofacial region, systemic disorders such as metabolic or endocrine abnormality should be considered.

Cortical integrity, periosteal reaction and soft tissue

Slow-growing lesions often cause expansion with cortical bowing, while cortical destruction denotes aggressive inflammatory or neoplastic lesions. Presence of periosteal reaction and soft tissue is also suggestive of an inflammatory or malignant aetiology. Some types of periosteal reactions are quite specific, like the sunburst type in osteosarcoma.

Effect on surrounding structures

Evaluating the effect of a lesion on the surrounding structure helps in inferring behaviour of the lesion. Displacement of teeth is seen more commonly with slow-growing, space-occupying lesions. Lesions with an epicentre above the crown of the tooth (i.e., dentigerous cyst and occasionally odontomas) displace the tooth apically. Lesions that start in the ramus, such as cherubism, may push teeth in the anterior direction. Resorption of the tooth usually occurs in more chronic and slow-growing processes; however, malignant lesions also occasionally resorb teeth. If a lesion involves only one tooth, it is important to note the degree of tooth development, relationship of the lesion with portion of tooth (crown vs. root vs. entire tooth) and any signs of tooth resorption. Malignant lesions can quickly grow down the ligament space, resulting in irregular widening and destruction of lamina dura. Widening of inferior alveolar canal with maintenance of a cortical boundary may indicate presence of benign lesion of vascular or neural origin.

Department of
Radiodiagnosis,
All India Institute of
Medical Sciences,
Ansari Nagar,
New Delhi 110029,
India

Neyaz Z, MD
Senior Resident

Gadodia A, MBBS
Junior Resident

Gamanagatti S, MD
Assistant Professor

Mukhopadhyay S, MD
Professor

Correspondence to:
Dr Shivanand
Gamanagatti
Tel: (91) 11 2686 4851
ext 4889
Fax: (91) 11 2686 2663
Email: shiv223@
rediffmail.com

Table I. Differential diagnosis of jaw lesions based on radiographical appearance.

Well-circumscribed radiolucent	Poorly-circumscribed radiolucent	Radiopaque	Mixed density
<ul style="list-style-type: none"> • Periapical cyst • Dentigerous cyst • Odontogenic keratocyst • Ameloblastoma • Incisive canal cyst • Simple bone cyst • Central giant cell granuloma 	<ul style="list-style-type: none"> • Acute osteomyelitis • Primary bone neoplasm • Direct tumor extension • Lytic metastasis 	<ul style="list-style-type: none"> • Odontoma • Torus • Osteoma • Osteochondroma • Cementoblastoma • Fibrous dysplasia (late) 	<ul style="list-style-type: none"> • Fibrous dysplasia • Ossifying fibroma • Cemento-osseous dysplasia • Chronic osteomyelitis • Osteosarcoma • Metastasis

Table II. Identification of radiolucent jaw lesions by location.

Unilocular	Multilocular
<ul style="list-style-type: none"> • Midline of maxilla superior to central incisors → Incisive canal cyst • Between maxillary lateral incisor and cuspid → globulomaxillary cyst • Mid palatal area → Mid palatal fissural cyst • Apex of non-vital teeth → periapical granuloma, periapical cyst • Apex of vital teeth → immature cementoma • Crown of impacted teeth → dentigerous cyst • Overlying mandibular canal → neurofibroma, neurilemmona • Inferior to mandibular canal in 2nd molar area → Stafne cyst • Focal or noncontiguous multiple → myeloma, LCH, metastasis 	<ul style="list-style-type: none"> • Anterior to 1st & 2nd molar → <ul style="list-style-type: none"> • CGCG • ABC • SBC • Brown tumour • Posterior involving ramus → <ul style="list-style-type: none"> • Ameloblastoma • Pindborg tumour • Odontogenic myxoma • Cherubism • No site predilection → <ul style="list-style-type: none"> • Fibrous dysplasia • Central haemangioma • OKC of basal cell naevus syndrome

In the following sections, the commonly-encountered jaw lesions will be discussed, with emphasis on their radiographical features.

CYSTS OF THE JAWS

Primordial cyst

A primordial cyst forms when a developing tooth undergoes cystic degeneration before the calcification.⁽⁵⁾ The most common location is the mandibular third molar and at the sites of supernumerary teeth. Radiographically, it is seen as a well-defined radiolucent lesion without an associated tooth (Fig. 1).

Radicular cyst

Radicular (periapical) cyst is the most common odontogenic cyst of the jaw. Most cysts (60%) are found in maxilla, especially around incisors and canines.⁽¹⁾ They are usually less than 1 cm in diameter, well-defined, unilocular lucent lesions in the periapical region associated with a

carious tooth (Fig. 2). The term residual cyst is used for a radicular cyst that has been left behind or that develops after extraction of a tooth.

Dentigerous cyst

Most dentigerous cysts manifest in adolescents and young adults, and often occur in the region of maxillary or mandibular third molar. On radiographs, it is seen as a well-defined, expansile, unilocular lucent lesion, associated with an unerupted teeth.⁽⁴⁾ An important diagnostic point is that the cyst attaches to cemento-enamel junction of the involved tooth with the crown projecting inside cystic cavity (Fig. 3). No associated periosteal reaction or soft tissue is seen.

Odontogenic keratocyst

The most common location of odontogenic keratocyst is the posterior mandibular body and ramus. Multiple

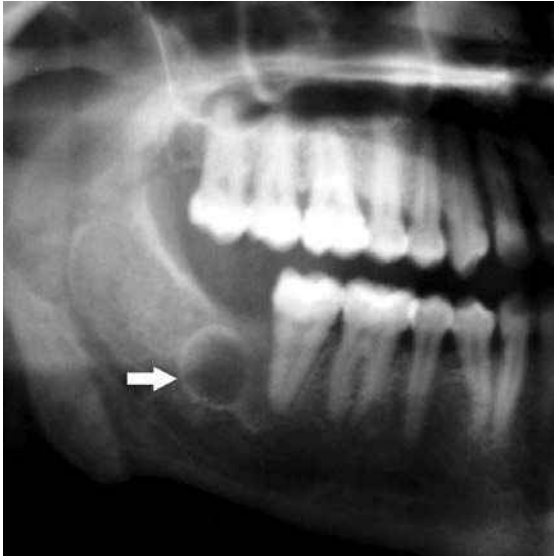


Fig. 1 Primordial cyst. Panoramic radiograph shows a well-defined radiolucency in the location of the right third molar which has failed to develop (arrow).

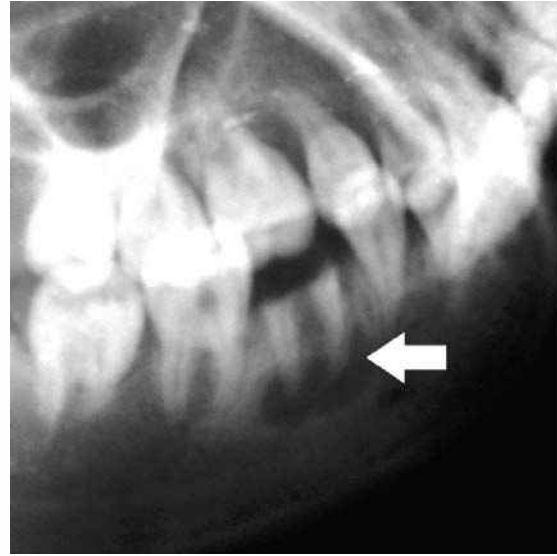


Fig. 2 Radicular cyst. Lateral oblique radiograph shows the development of a small well-corticated, lucent lesion around the root apex of a carious tooth (arrow).

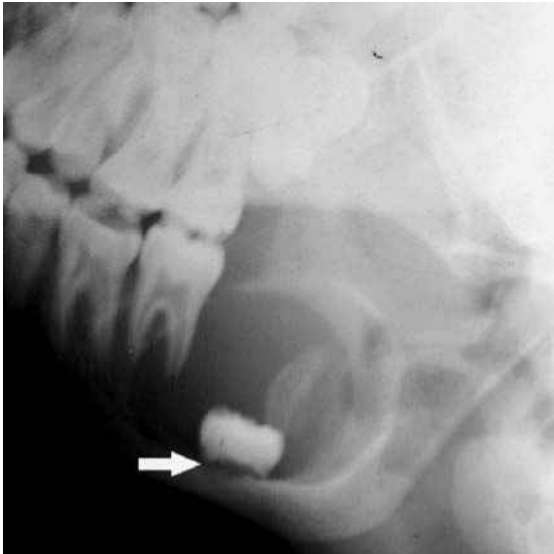


Fig. 3 Dentigerous cyst. Lateral oblique radiograph shows a well-defined expansile lucent lesion in the left mandible. Note unerupted third molar with the crown lying inside the cyst (arrow).

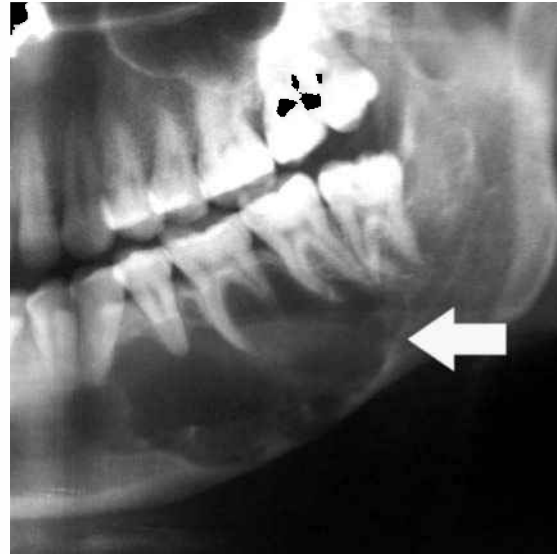


Fig. 4 Odontogenic keratocyst in a 36-year-old woman. Panoramic radiograph shows an ellipsoid, expansile, well-corticated, lucent lesion in left mandibular body (arrow).

lesions are associated with basal cell nevus syndrome (Gorlin-Goltz syndrome). Radiographically, it presents as a well-circumscribed, unilocular or multilocular lucent lesion with well-corticated borders (Fig. 4). However, it can mimic a primordial cyst if associated with absence of a tooth, a dentigerous cyst if it occurs pericoronally, or an ameloblastoma.⁽⁴⁾ An important feature of the odontogenic keratocyst is its tendency to grow in a predominantly anteroposterior direction while causing minimal cortical expansion.

Simple bone cyst

Simple bone cyst is also known as traumatic or haemorrhagic bone cyst. The exact aetiology is unknown. However, it is believed to be secondary to localised trauma,

leading to intramedullary haemorrhage and subsequent resorption of bone.^(4,6) On radiographs, it presents as a well-defined radiolucent lesion, mostly in the posterior mandible. Characteristic imaging findings are extension between roots of adjacent teeth, preservation of lamina dura and internal cortical scalloping.

ODONTOGENIC TUMOURS

Odontoma

Odontomas are considered to be a hamartomatous lesion rather than a neoplasm.⁽¹⁾ Most cases are diagnosed in the second decade of life, and are usually associated with an impacted tooth. Radiologically, it is seen as a radiopaque mass surrounded by thin radiolucent space. The compound odontomas are composed of multiple well-formed teeth

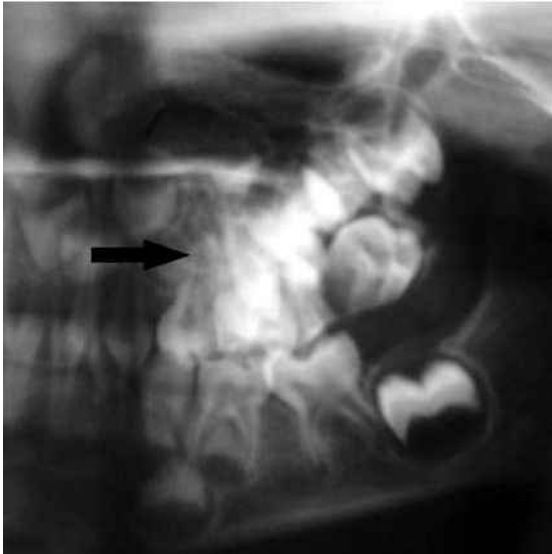

Fig. 5 Compound odontoma. Panoramic radiograph shows multiple tooth-like structures in the left maxillary region.

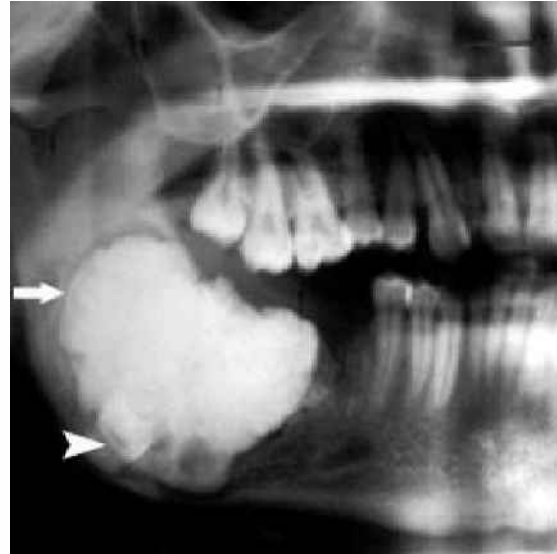


Fig. 6 Complex odontoma. Panoramic radiograph shows a radiopaque mass in the anterior ramus and body of right mandible. Note the thin radiolucent space around the calcified mass (arrow) and impacted tooth (arrowhead).

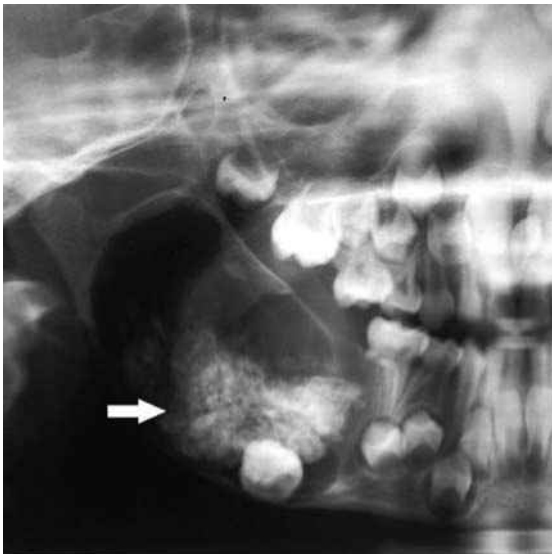

Fig. 7 Ameloblastic fibro-odontoma in a young boy. Panoramic radiograph shows there is a large amount of radiolucent component with expansion of mandibular ramus. The odontoma component is complex in nature (arrow).

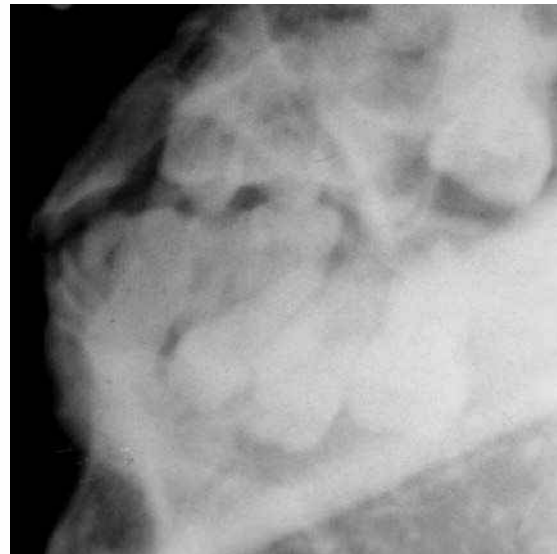


Fig. 8 Multicystic ameloblastoma in a 55-year-old man. Lateral oblique radiograph shows an expansile multiloculated cystic lesion with osseous septation in the left mandibular body and ramus. There is marked cortical thinning and loss of tooth.

(Fig. 5), whereas the complex odontomas appear as an irregular calcified tissue (Fig. 6). A related but very rare lesion is ameloblastic fibro-odontoma. Most cases occur in young males involving posterior jaws and may expand into the ramus⁽⁵⁾ The amount of radiolucent internal structure exceeds the odontomas component (Fig. 7).

Ameloblastoma

The majority of ameloblastoma are benign, with less than 1% showing malignant behaviour.⁽⁴⁾ The most common site of ameloblastoma is the ascending ramus and proximal body of the mandible (80%). Ameloblastomas are divided into two subtypes, based on radiological appearance. Multicystic ameloblastomas account for

approximately 85% of all ameloblastomas and occur in the third to seventh decades of life. On radiographs, there is marked buccolingual cortical expansion with internal osseous septae, giving rise to a “soap bubble” appearance (Fig. 8). Tooth displacement or root resorption may occur. Unicystic ameloblastomas occur in a younger age group and tend to be non-invasive. They present as a well-circumscribed, unicystic, radiolucent lesion, mostly in the region of the mandibular third molar (Fig. 9).

Odontogenic myxoma

Odontogenic myxoma is a rare, locally-aggressive benign tumour and manifests in the second to fourth decades of life.⁽⁵⁾ Clinically and radiologically, it closely resembles

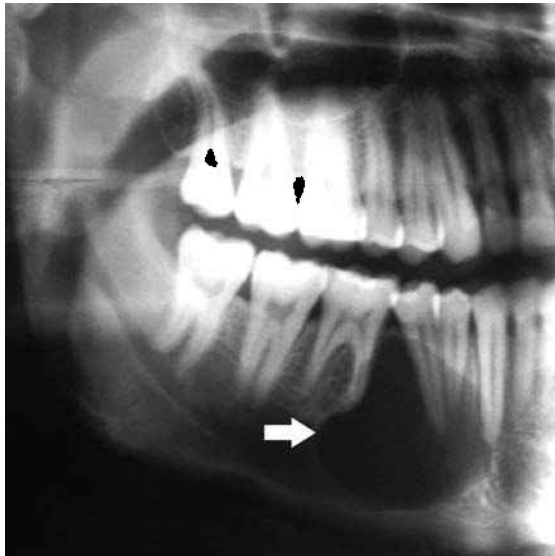


Fig. 9 Unicyclic ameloblastoma in a 25-year-old man. Panoramic radiograph shows a well-defined lucent lesion between the canine and first premolar (arrow). Note the loss of lamina dura with tooth displacement.

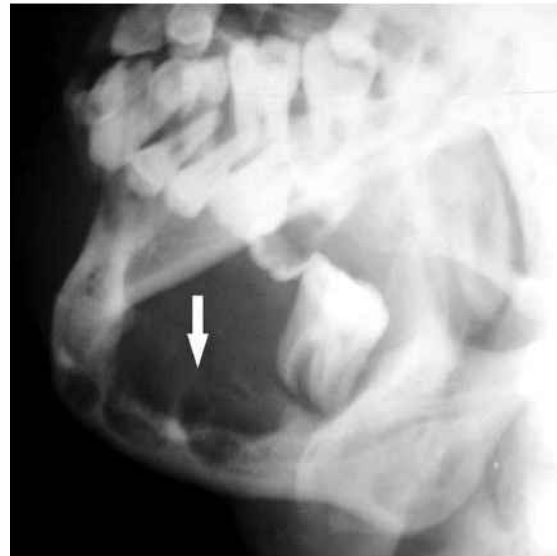

Fig. 10 Odontogenic myxoma. Lateral oblique radiograph shows an expansile lesion in right mandible with thin bony septae (arrow).

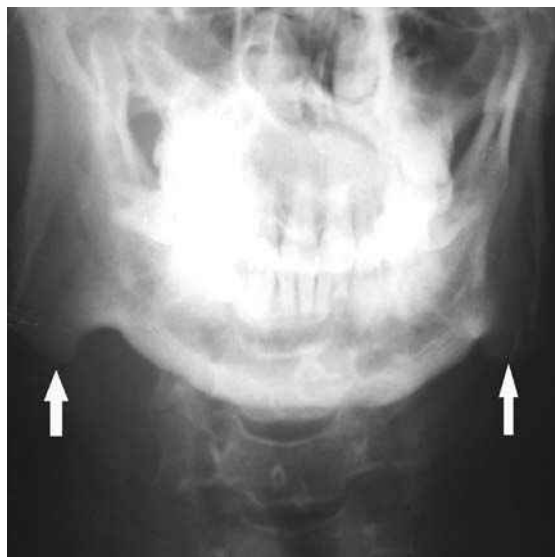


Fig. 11 Prominent mandibular angle. Radiograph shows enlargement and lateral flaring of the bilateral mandibular angles (arrows).

ameloblastoma.⁽⁶⁾ Myxomas occur more commonly in the mandible, with tooth-bearing area involved mostly. It appears as multilocular radiolucency with well-developed internal bony septae which may be lost as the lesion grows (Fig. 10). Root resorption and teeth displacement may occur.

TUMOURS AND OTHER LESIONS RELATED TO BONE

Prominent mandibular angle

A prominent mandibular angle is sometimes encountered in the oriental population and produces a characteristic square, coarse, and muscular appearance of the face.^(7,8) On radiographs, the mandibular angle projects posterior with lateral flaring (Fig. 11). Mandibular angle resection

has described in female patients for cosmetic reasons.

Osteoma

An osteoma is a benign bone-forming tumour that almost always occurs in the skull and face.^(1,4) The common location in jaw includes the lingual side of the ramus or the inferior mandibular border below the molars. These lesions are usually asymptomatic and can occur at any age. Radiologically, an osteoma is seen as a well-defined, dense, radiopaque mass (Fig. 12). Multiple osteomas should raise the possibility of Gardner syndrome.

Torus

Tori are exostosis in specific locations in the jaw and are named accordingly.⁽¹⁾ Torus palatinus are nodular bony protuberances arising in the middle of the hard palate. Torus mandibularis are located on the lingual aspect of the mandible and usually bilateral (Fig. 13).⁽⁶⁾

Cemento-ossifying fibroma

Previously, these lesions were classified into ossifying fibroma and cementifying fibroma depending on whether bone or cementum was the predominant calcified product. However, now the two are thought to represent a spectrum of one disease.⁽¹⁾ Cemento-ossifying fibroma (COF) occurs predominantly in women in the third and fourth decades of life.⁽⁹⁾ COF almost exclusively occurs in the facial bone, with the mandible being most commonly affected, typically inferior to molars and premolars, and superior to the inferior alveolar canal. COF is seen as a well-defined expansile lesion, often surrounded by a thick or thin radiodense rim.⁽⁹⁾ The internal structure is a mixture of radiolucent and radiopaque density depending on the stage of development and amount of mineralised matrix (Fig. 14). When the lesion contains a large amount of cementum-like material, it shows markedly increased

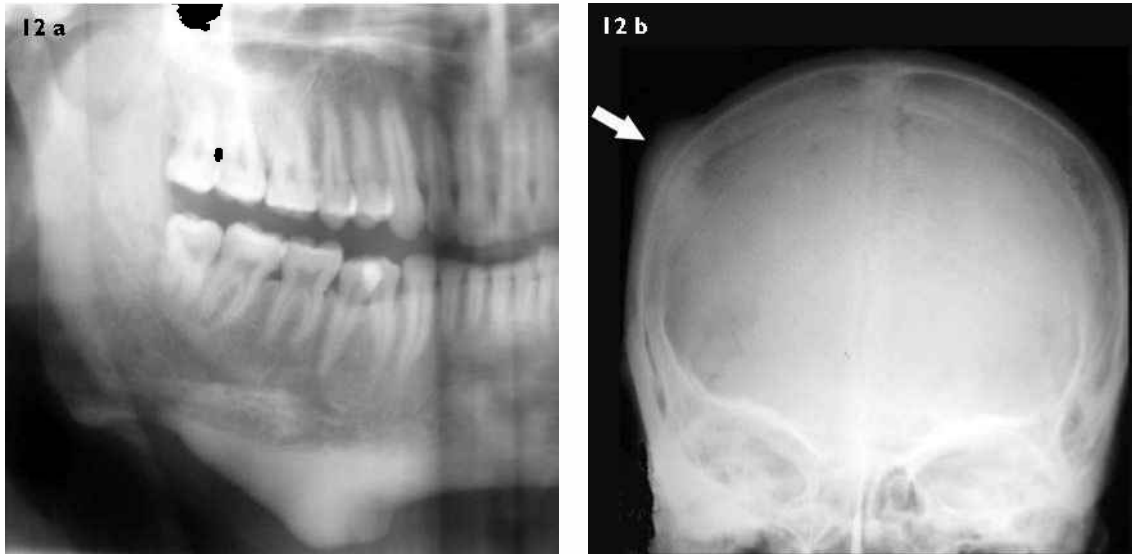


Fig. 12 Multiple osteomas in Gardner syndrome. (a) Panoramic radiograph shows a compact osteoma attached to the inferior mandibular border. (b) A posteroanterior skull radiograph shows another osteoma in the right parietal region (arrow).

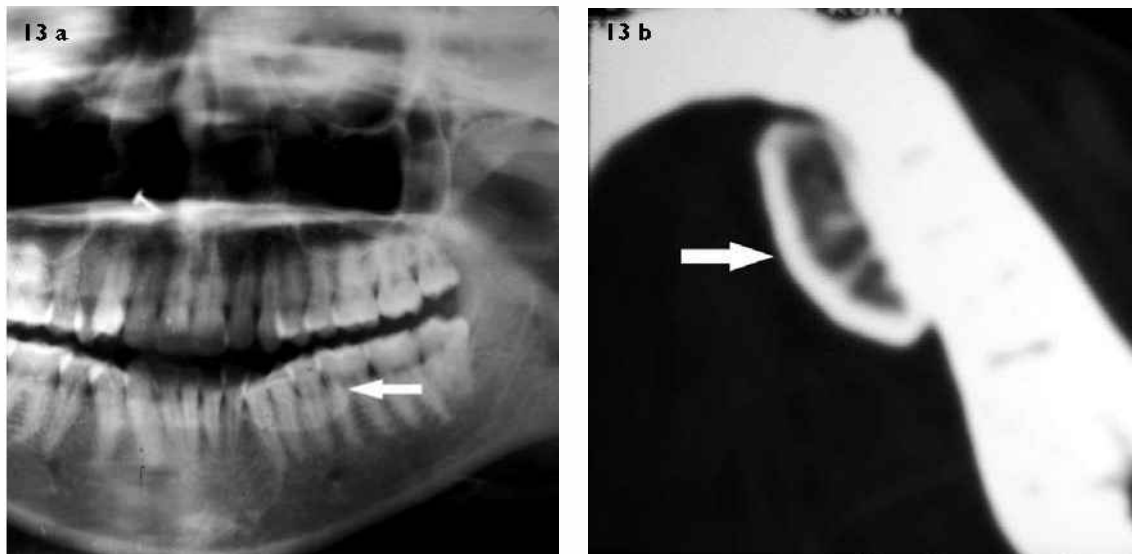


Fig. 13 Torus mandibularis. (a) Panoramic radiograph shows a dense radiopacity (arrow) superimposed on the premolar region. (b) Axial CT image shows the attachment to the lingual surface of the mandible. (arrow).

density (Fig. 15). Large mandibular lesions demonstrate a downward bowing of inferior border. The differential diagnosis of the ossifying fibroma is primarily with fibrous dysplasia (FD). In COF, there is usually a moderately thick radiodense rim, whereas FD blends with surrounding bone. FD usually maintains the shape of the outer wall of the involved bone, whereas COF has a more convex shape, as it behaves like a tumour rather than dysplasia.

Fibrous dysplasia

FD is an idiopathic, nonheritable condition, in which normal bone is replaced with fibro-osseous tissue.⁽⁹⁾ FD mostly affects patients younger than 30 years of age, and may be a monostotic (70%) or polyostotic type (30%). Association of polyostotic FD with endocrine disorders

and cutaneous hyperpigmentation is known as the McCune-Albright syndrome. It occurs more frequently in the maxilla than in the mandible. Radiographical changes range from lucent zones to diffuse areas of sclerosis, depending on amount of fibrous tissue and bony matrix. Radiographically, craniofacial FD has been classified into three types: pagetoid, sclerotic, and cyst-like. The pagetoid type is characterised by bone expansion and alternate areas of radiodensity and radiolucency. The sclerotic type appears as bone expansion with homogeneous radiodensity, giving the classic “ground-glass appearance” (Fig. 16). The cyst-like lesion appears as solitary, round or oval well-defined radiolucent lesion with sclerotic margin. In FD, the cortex remains intact and no periosteal reaction is seen.

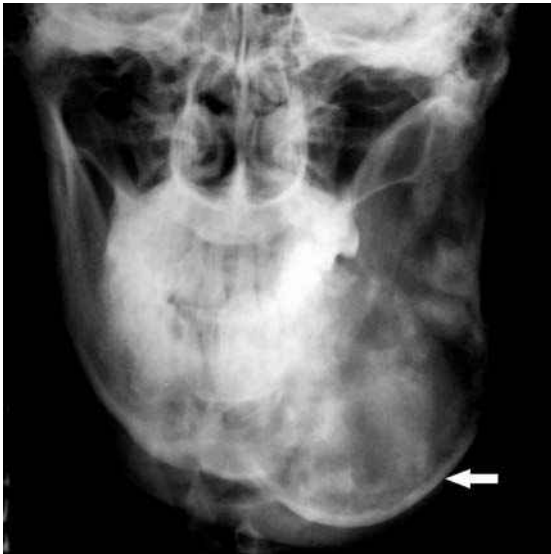

Fig. 14 Cemento-ossifying fibroma. Radiograph shows an expansile radiolucent lesion in the left mandible with characteristic inferior bowing of the lower border. Lesions shows flocculent pattern of internal matrix mineralisation with a moderately thick sclerotic rim (arrow).

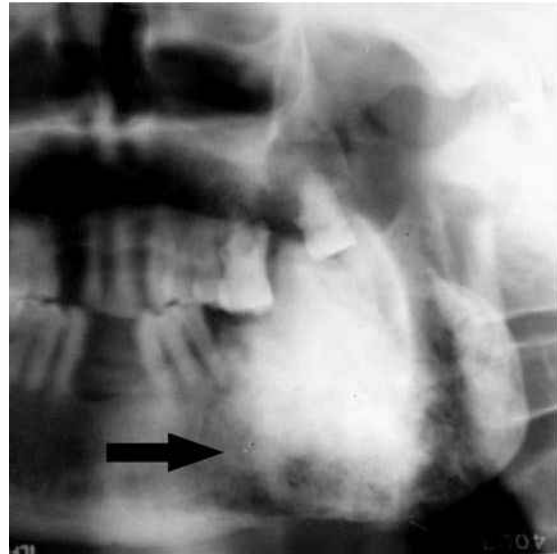


Fig. 15 Cemento-ossifying fibroma. Panoramic radiograph shows a solid amorphous radio-opacity (cementum-like pattern) with a radiolucent band at the periphery (arrow).

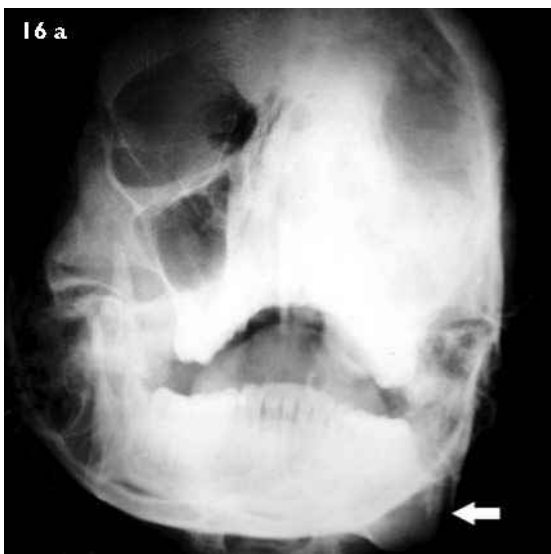
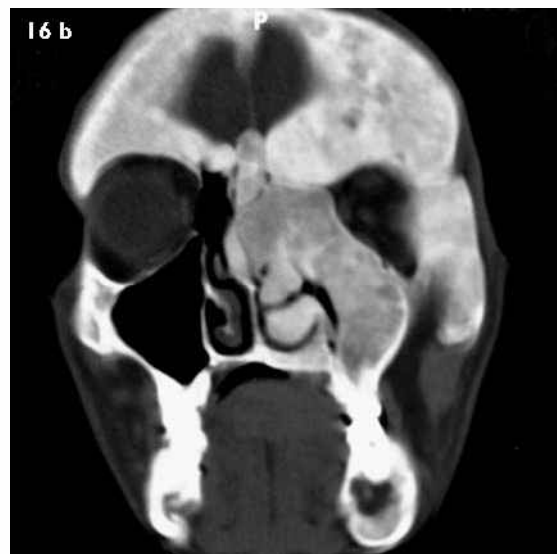


Fig. 16 Craniofacial fibrous dysplasia. (a) Waters view radiograph shows expansion and radiopacity with a ground glass appearance of left maxillary sinus, nasal bone, frontal bone, zygomatic process and the left mandible (arrow). (b) Coronal CT image (bone window) shows osseous expansion, cortical thinning and areas of varying radiopacity reflecting the degree of maturation of fibrous tissue.



Cherubism

Cherubism is a rare, inherited developmental abnormality developing in early childhood (2–6 years of age) and lesions tend to regress with age.⁽¹⁾ It is almost always bilaterally symmetrical with an epicentre in the ramus of the mandible or tuberosity of maxilla. Lesions are usually well-defined, expansile, with fine trabeculae forming a multilocular pattern (Fig. 17).

Periapical cemento-osseous dysplasia

It occurs around the root apices of vital tooth in middle-aged women with a predilection for mandibular incisors.^(1,4) In the early stage, it appears as a well-defined radiolucent lesion which gradually becomes totally radiopaque with a thin lucent rim. Florid cemento-osseous dysplasia is a

diffuse form characterised by multiple periapical lesions involving one entire jaw.

Osteogenic sarcoma

Osteogenic sarcoma is an osteoid-producing highly malignant tumour of the bone. Primary osteogenic sarcoma of the jaw is quite uncommon, with peak incidence between 30 and 39 years of age.⁽⁴⁾ Lesions can occur anywhere in jaw but the posterior part of the mandible is most commonly affected. Osteogenic sarcoma can cause lytic bone destruction with indefinite margins (osteolytic type), areas of sclerosis (osteoblastic type), or a mixed pattern.⁽¹⁰⁾ The osteoblastic type is the most common in the jaw and may show a sunburst type of periosteal reaction caused by radiating mineralised spicules (Figs. 18 & 19).

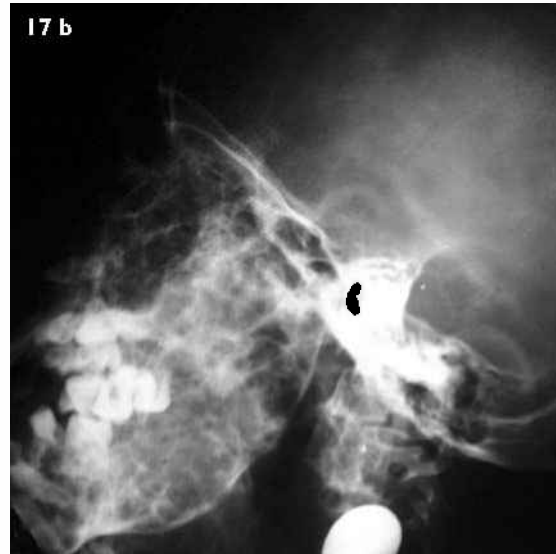
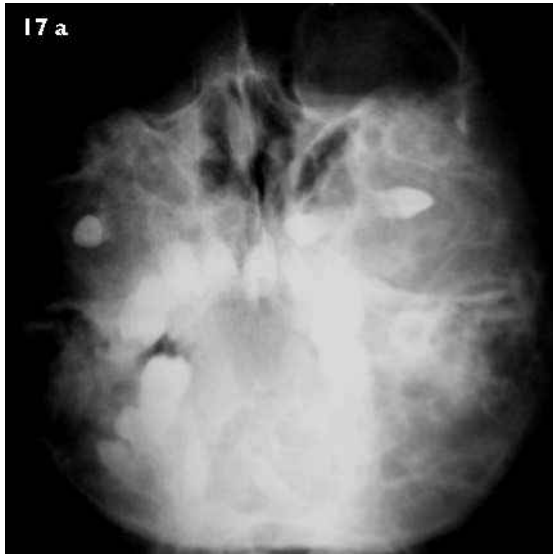

Fig. 17 Cherubism. (a) Posteroanterior and (b) lateral radiographs show expansile multilocular lesions in bilateral mandibular ramus and maxillary tuberosity. Note the anterior displacement of teeth.

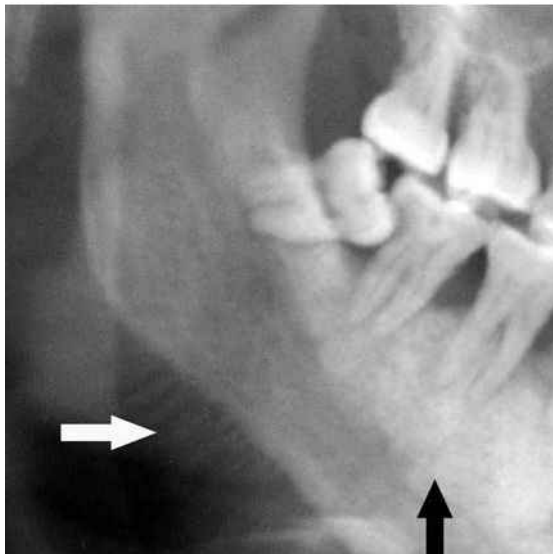


Fig. 18 Osteosarcoma in a 30-year-old man. Panoramic radiograph shows a sclerotic lesion (black arrow) in the right mandible and sunray spicules (white arrow). Incidental impacted third molar is also noted.

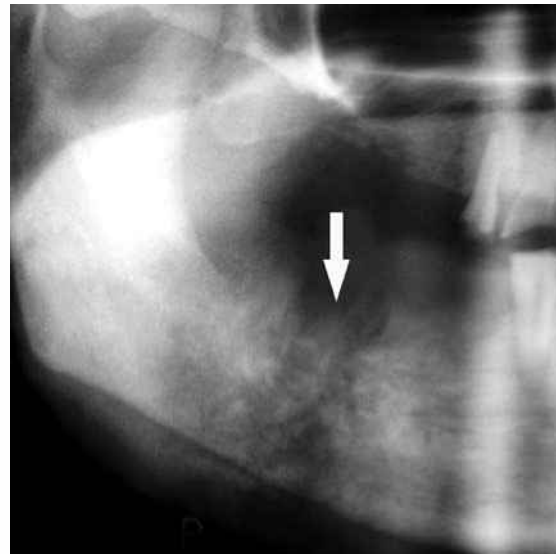


Fig. 19 Osteosarcoma in a 50-year-old man. Radiograph shows a mixed lytic-sclerotic lesion in the right mandible with spiculated periosteal reaction (arrow).

In early stage, findings may be a very subtle widening of the periodontal ligament or a localised radiolucency around one or more teeth.

Direct neoplastic extension from adjacent soft tissue

Advance carcinomas arising in the oral cavity and maxillary sinus frequently invade the mandible and maxilla.⁽¹⁰⁾ The osseous involvement manifests early at the alveolar ridge with a saucer-shaped erosive defect (Fig. 20). The radiographical appearances may include an irregular cavity of variable size, multiple lytic foci which may coalesce to form a large irregular lesion, and moth-eaten appearance. There is usually no evidence of bony sclerosis or periosteal reaction. Similarly, other malignant soft tissue lesions can also invade jaw and cause destruction.

Metastatic jaw tumours

Metastases to the mandible are four times more common than to the maxilla, and the most common primary tumour sites are the breast, lung, kidney, thyroid and prostate.⁽¹⁰⁾ In most instances, the lesions are radiolucent with ill-defined margins; however, mixed osteolytic and osteoblastic, or diffuse osteoblastic metastasis, may be seen.

Multiple myeloma

Multiple myeloma is a malignant neoplasm of plasma cells, with peak incidence in the sixth decade of life. In the jaw, the mandible is more commonly affected. Multiple myeloma is characterised by multiple punched-out, oval or rounded radiolucent lesions without any surrounding bone reaction.⁽¹⁰⁾ A localised form of this disorder is known as solitary plasmacytoma of bone (SPB), which is potentially

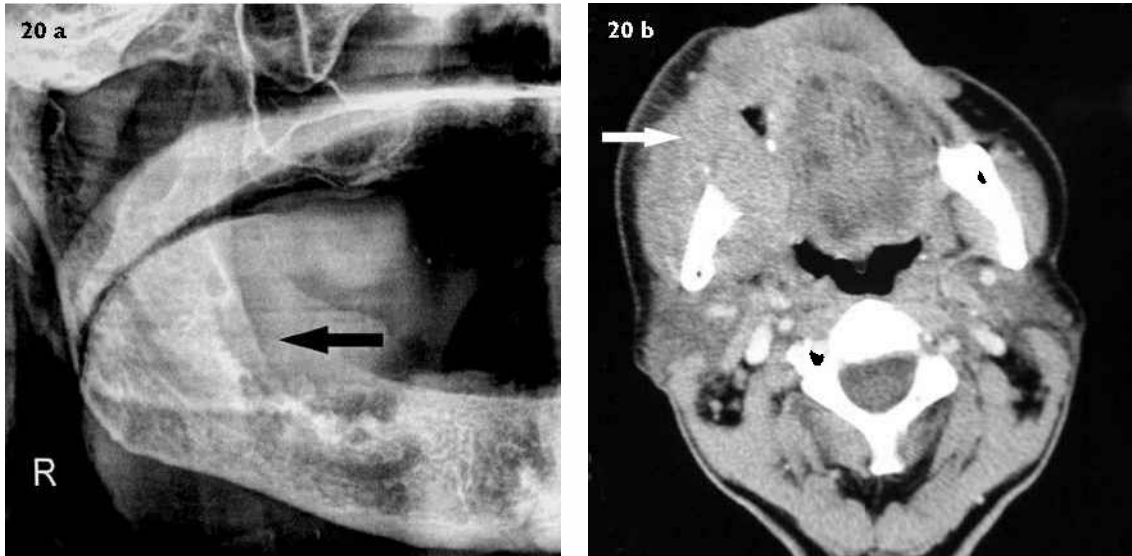

Fig. 20 Direct neoplastic extension from squamous cell carcinoma of gingiva. (a) Panoramic radiograph shows an irregular lytic lesion of right alveolar margin (arrow). (b) Axial contrast-enhanced CT image shows an enhancing soft tissue mass causing destruction of right mandible (arrow).

capable of progressing into generalised myelomatosis. Three main radiographical presentations of SPB of jaw are multilocular soap bubble lesions, unilocular radiolucency with a cystic appearance, and ill-defined destructive bone resorption (Fig. 21).⁽¹¹⁾

Eosinophilic granuloma

Eosinophilic granuloma is a benign form of Langerhans' cell histiocytosis, and usually occurs in children and young adults.⁽¹⁾ Radiologically, these lesions are totally radiolucent and the margins may be smooth or somewhat irregular. Based on the location, jaw lesions are divided into the alveolar and intraosseous types. The alveolar type of lesions are commonly multiple and involve the alveolar process, whereas intraosseous lesions occur elsewhere in jaw. Alveolar type commonly starts in mid-root region of tooth and with progression, a scooped-out appearance of alveolar process is seen (Fig. 22). The bone around the teeth, including lamina is destroyed; as a result, the "floating teeth appearance" may be seen. Intraosseous type lesions are usually solitary with mandibular ramus most commonly involved. Intraosseous lesion may be irregular, oval or round and may stimulate periosteal bone formation.

Central giant cell granulomas

Central giant cell granulomas (CGCG) typically occur in patients younger than 30 years of age, more often in females.⁽¹²⁾ The lesion is more common in the anterior part of mandible with a tendency to cross the midline.⁽¹³⁾ In the early stage, the lesion manifests as a small unilocular lucent lesion. However, with development, it appears multilocular with fine trabeculae. They may cause a variable degree of bony expansion, divergence of roots and root resorption (Fig. 23). Brown tumour of hyperparathyroidism can mimic CGCGs radiologically

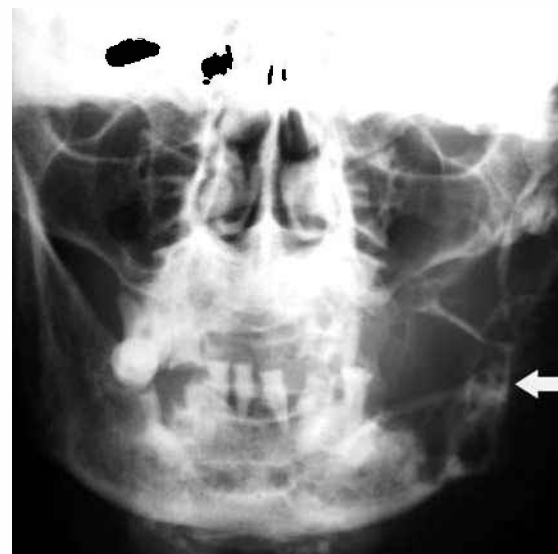

Fig. 21 Solitary plasmacytoma of the bone in a 60-year-old man. Anteroposterior radiograph shows an expansile lytic lesion of left mandible with apparent trabeculations (arrow).

as well as pathologically; however, the patient's age, radiological changes in other bones, and biochemical findings help in differentiation.

Arteriovenous malformations

Arteriovenous malformation (AVM) is an abnormal communication between an artery and vein. Recognition of an AVM is important because extraction of an associated tooth may lead to fatal haemorrhage.^(6,13) Radiographically, it appears as a multilocular cystic lesion, and angiography is usually necessary to demonstrate the vascular nature of the lesion (Fig. 24).

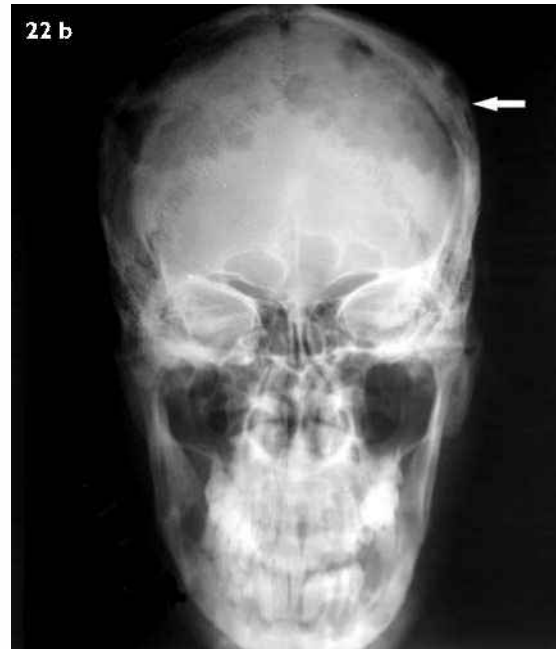
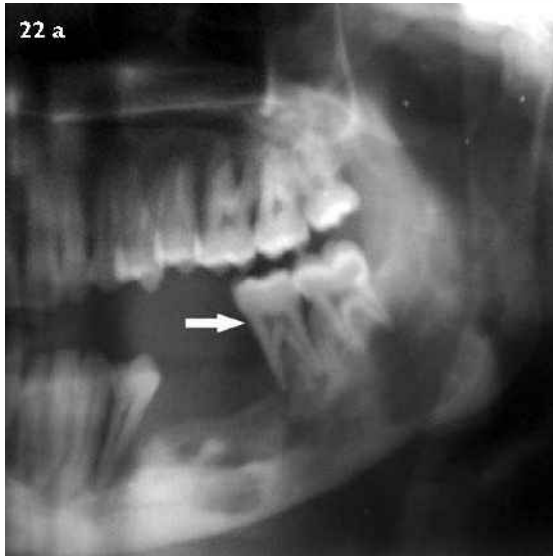
Fig. 22 Eosinophilic granuloma. (a) Panoramic radiograph shows destruction of the alveolar process with loss of bone and lamina dura around remaining mandibular teeth (arrow). (b) Radiograph shows the characteristic lytic lesions with beveled edges in the calvarium (arrow).

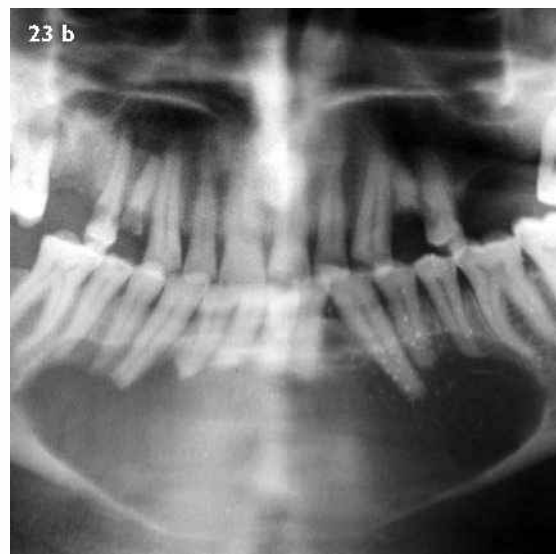
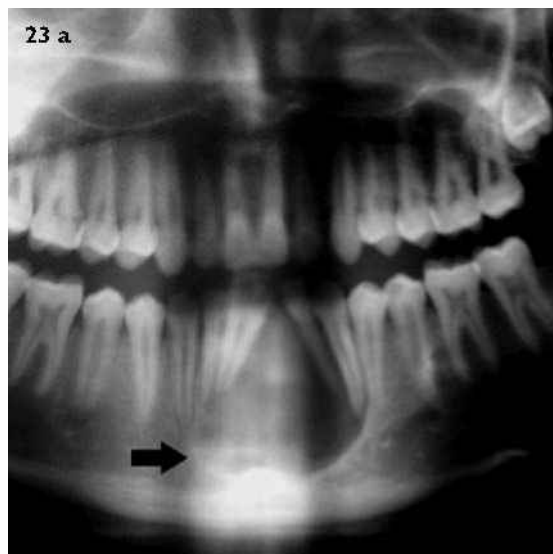

Fig. 23 Central giant cell granuloma. (a) Panoramic radiograph shows a unilocular radiolucent lesion anterior part of mandible causing divergence of roots of adjacent teeth (arrow). (b) Radiograph of a different patient shows a large midline destructive lesion causing displacement of teeth and root resorption.

INFLAMMATORY LESIONS

Periapical sclerosing osteitis

Sclerosing osteitis occurs as a response of bone around the apex of a tooth secondary to periodontal disease.⁽¹⁾ It is characterised by sclerosis in the periapical region of the involved tooth (Fig. 25).

Acute osteomyelitis

In the jaw, osteomyelitis is more common in the mandible, mostly secondary to a tooth abscess or post-surgical infection. Radiographical findings usually appear 1–2 weeks later and include ill-definition of trabeculae, single or multiple ill-defined radiolucent areas, and loss of lamina dura between the tooth and adjacent lesion.⁽⁴⁾ Later

in the disease course, there may be sclerosis, sequestrum formation and periosteal reaction.

Chronic osteomyelitis

Chronic osteomyelitis results from either an inadequately-treated acute infection or a long-term low-grade infection.^(4,14) Three forms of chronic osteomyelitis have been described in the jaw, viz., (1) chronic sclerosing osteomyelitis presents as mixed sclerotic and lytic zones or have a predominantly sclerotic component; (2) chronic suppurative osteomyelitis is characterised by areas of bone destruction, sequestrum formation and periosteal reaction (Fig. 26); and (3) Garre's osteomyelitis occurs in children and adolescents, and are radiographically

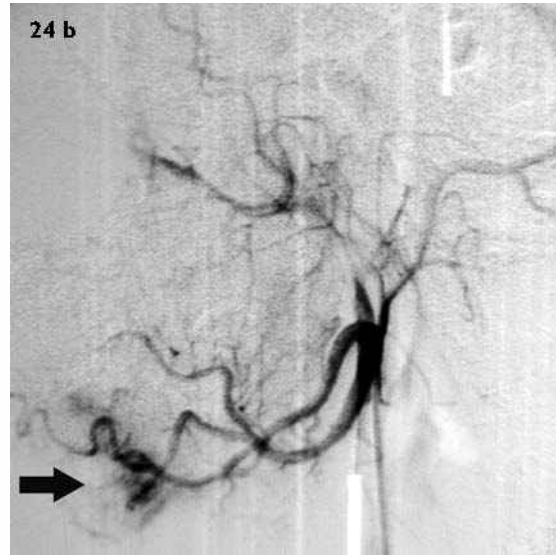
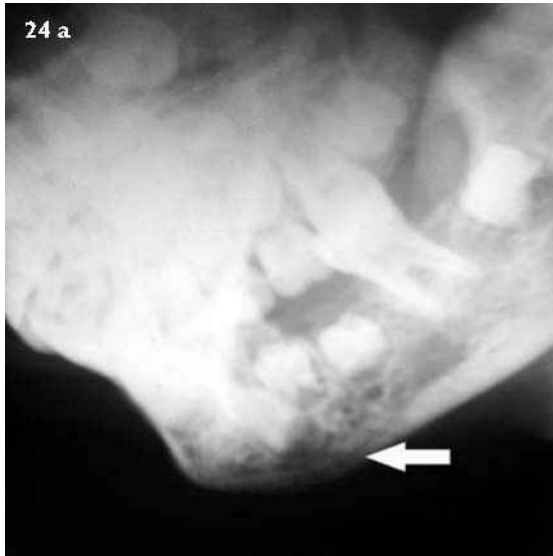

Fig. 24 Arteriovenous malformation. (a) Lateral oblique radiograph of the mandible shows multilocular cystic lesion with poorly-defined margins (arrow). (b) External carotid angiogram (different patient) shows an abnormal bunch of vessels supplied by the lingual artery.

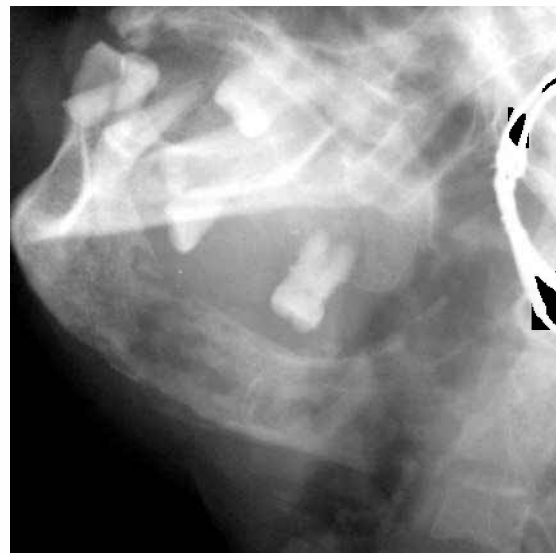
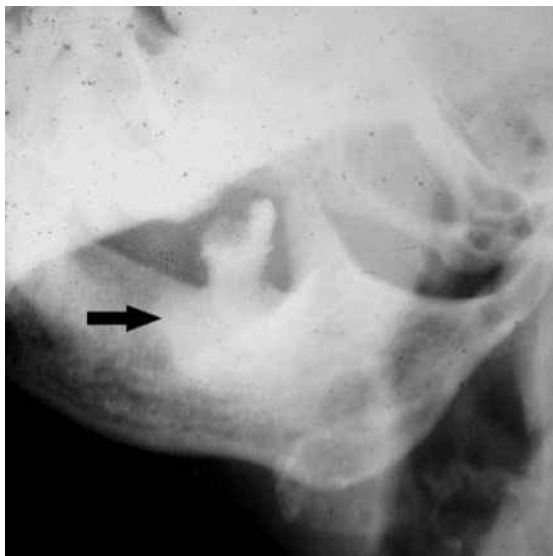


Fig. 25 Periapical sclerosing osteitis. Marked sclerosis seen around the apex of a carious third molar (arrow).

Fig. 26 Chronic suppurative osteomyelitis. Lateral oblique radiograph shows scattered areas of bone destruction and sclerosis with sequestrum formation.

seen as significant cortical thickening resulting from multilamellar periosteal reaction. Osteoradionecrosis refers to an inflammatory process that occurs following heavy radiation of bone.⁽¹⁵⁾ Radiographically, it has many similarities with chronic osteomyelitis, but history of radiotherapy is important for differentiation.

SYSTEMIC DISEASES MANIFESTED IN THE JAWS

Brown tumours

Brown tumours are reactive bony lesions caused by long standing primary or secondary hyperparathyroidism and do not have neoplastic potential.^(1,9) There may be multiple lesions in a single bone. These lesions have variable well-defined or ill-defined margins, and may produce cortical expansion (Fig. 27). Associated changes, such as decreased

density of jaw, granular texture of bony trabeculae, and loss of lamina dura along with biochemical parameters, help in correct diagnosis.

Osteopetrosis

Osteopetrosis is characterised by a generalised increase in bone mass due to abnormal osteoclast function.⁽¹⁾ These dense bones are more susceptible to osteomyelitis due to poor vascularity (Fig. 28). A diffuse osteosclerosis may also be seen in other sclerosing bony dysplasias, fluorosis and renal osteodystrophy.

SUMMARY

The radiological diagnosis of various jaw lesions is based on the patient's history, the location of lesion, its internal architecture, and characteristic radiographical alteration

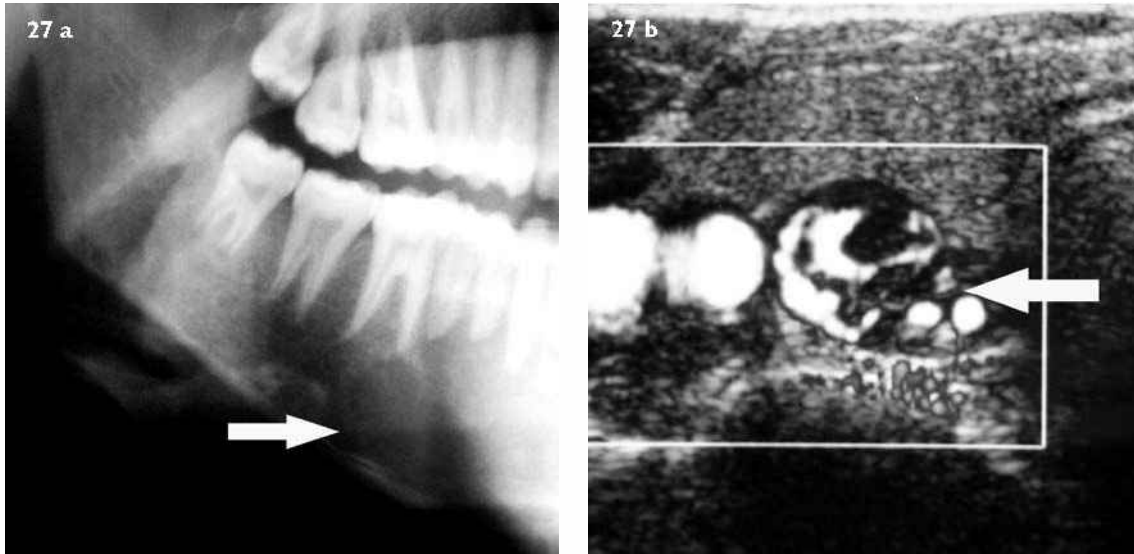


Fig. 27 Brown tumour of hyperparathyroidism. (a) Panoramic radiograph shows an expansile lucent lesion with indistinct margins in right mandibular body (arrow). (b) Ultrasonography image shows a hypervascular right parathyroid adenoma (arrow).

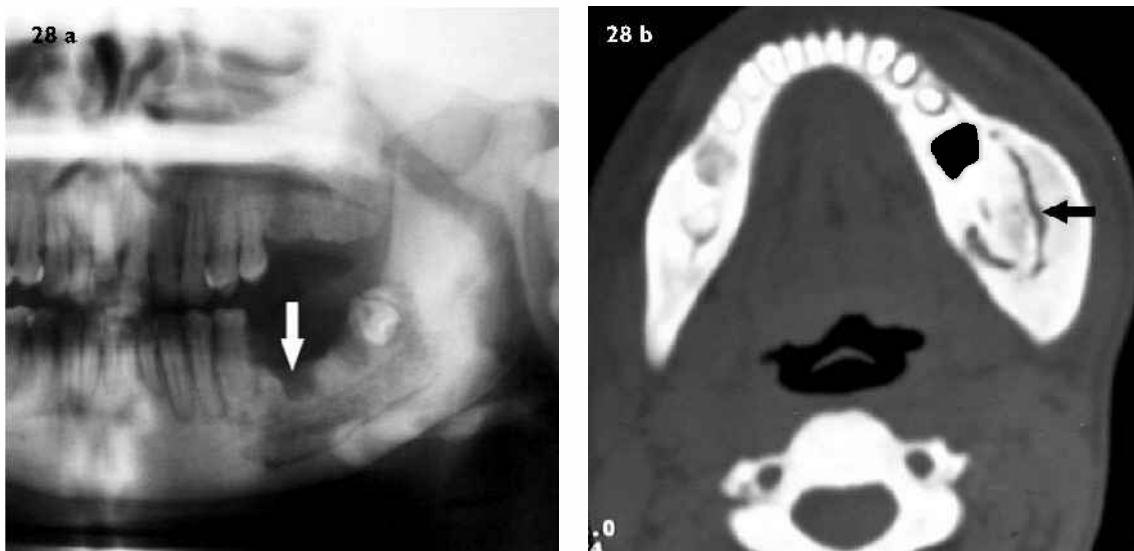


Fig. 28 Osteopetrosis. (a) Panoramic radiograph shows dense facial bones with a sequestrum in left mandible suggestive of chronic osteomyelitis. (b) Axial CT image shows the sequestrum more clearly (arrow).

of adjacent structures. It is not always possible to pinpoint a single diagnosis. However, by careful evaluation of the jaw lesion, the list of differentials can be further narrowed.

REFERENCES

- White SC, Pharaoh MJ. Oral Radiology. Principles and Interpretation. 4th ed. St Louis: Mosby, 2000.
- Preece JW. Dental radiographic techniques and normal roentgen anatomy. *Semin Roentgenol* 1971; 6:359-69.
- Eversole LR, Rovin S. Differential radiographic diagnosis of lesions of the jawbones. *Radiology* 1972; 105:277-84.
- DelBalso AM. An approach to the diagnostic imaging of jaw lesions, dental implants, and the temporomandibular joint. *Radiol Clin North Am* 1998; 36:855-90.
- Weber AL. Imaging of cysts and odontogenic tumors of the jaw. Definition and classification. *Radiol Clin North Am* 1993; 31: 101-20.
- Dunfee BL, Sakai O, Pistey R, Gohel A. Radiologic and pathologic characteristics of benign and malignant lesions of the mandible. *Radiographics* 2006; 26:1751-68.
- Baek SM, Kim SS, Bindiger A. The prominent mandibular angle: preoperative management, operative technique, and results in 42 patients. *Plast Reconstr Surg* 1989; 83:272-80.
- Kim SK, Han JJ, Kim JT. Classification and treatment of prominent mandibular angle. *Aesthetic Plast Surg*. 2001; 25:382-7.
- Mafee MF, Yang G, Tseng A, Keiler L, Andrus K. Fibro-osseous and giant cell lesions, including brown tumor of the mandible, maxilla, and other craniofacial bones. *Neuroimaging Clin N Am* 2003; 13:525-40.
- Weber AL, Bui C, Kaneda T. Malignant tumors of the mandible and maxilla. *Neuroimaging Clin N Am* 2003; 13:509-24.
- Lae ME, Vencio EF, Inwards CY, Unni KK, Nascimento AG. Myeloma of the jaw bones: a clinicopathologic study of 33 cases. *Head Neck* 2003; 25:373-81.
- Cohen MA, Hertzanu Y. Radiologic features, including those seen with computed tomography, of central giant cell granuloma of the jaws. *Oral Surg Oral Med Oral Pathol* 1988; 65:255-61.
- Scholl RJ, Kellett HM, Neumann DP, Lurie AG. Cysts and cystic lesions of the mandible: clinical and radiologic-histopathologic review. *RadioGraphics* 1999; 19:1107-24.
- Schuknecht B, Valavanis A. Osteomyelitis of the mandible. *Neuroimaging Clin N Am* 2003; 13:605-18.
- Hermans R. Imaging of mandibular osteoradionecrosis. *Neuroimaging Clin N Am* 2003; 13:597-604.

SINGAPORE MEDICAL COUNCIL CATEGORY 3B CME PROGRAMME
Multiple Choice Questions (Code SMJ 200802B)

	True	False
Question 1. What differentials will you consider in a well-circumscribed radiolucent lesion of the jaw?		
(a) Dentigerous cyst.	<input type="checkbox"/>	<input type="checkbox"/>
(b) Metastasis.	<input type="checkbox"/>	<input type="checkbox"/>
(c) Ameloblastoma.	<input type="checkbox"/>	<input type="checkbox"/>
(d) Acute osteomyelitis.	<input type="checkbox"/>	<input type="checkbox"/>
 Question 2. Regarding odontogenic keratocyst:		
(a) It can mimic a primordial cyst, a dentigerous cyst or an ameloblastoma.	<input type="checkbox"/>	<input type="checkbox"/>
(b) The most common location is the posterior mandibular body and ramus.	<input type="checkbox"/>	<input type="checkbox"/>
(c) Multiple lesions are associated with the Gorlin-Goltz syndrome.	<input type="checkbox"/>	<input type="checkbox"/>
(d) It causes marked cortical expansion.	<input type="checkbox"/>	<input type="checkbox"/>
 Question 3. Regarding systemic diseases affecting the jaw:		
(a) Brown tumours are caused by long-standing hyperparathyroidism.	<input type="checkbox"/>	<input type="checkbox"/>
(b) Brown tumours have neoplastic potential.	<input type="checkbox"/>	<input type="checkbox"/>
(c) In hyperparathyroidism after appropriate therapy, all radiographical changes tend to return to normal.	<input type="checkbox"/>	<input type="checkbox"/>
(d) Osteopetrosis predisposes bones to osteomyelitis.	<input type="checkbox"/>	<input type="checkbox"/>
 Question 4. What differential diagnosis will be considered in multiple lytic lesions involving the jaw?		
(a) Multiple myeloma.	<input type="checkbox"/>	<input type="checkbox"/>
(b) Langerhans cell histiocytosis.	<input type="checkbox"/>	<input type="checkbox"/>
(c) Ameloblastoma.	<input type="checkbox"/>	<input type="checkbox"/>
(d) Metastasis.	<input type="checkbox"/>	<input type="checkbox"/>
 Question 5. Regarding odontomas:		
(a) These are hamartomatous lesions.	<input type="checkbox"/>	<input type="checkbox"/>
(b) Complex odontomas are composed of multiple well-formed teeth.	<input type="checkbox"/>	<input type="checkbox"/>
(c) Odontomas do not tend to recur after surgical resection.	<input type="checkbox"/>	<input type="checkbox"/>
(d) Odontoma is premalignant lesion.	<input type="checkbox"/>	<input type="checkbox"/>

Doctor's particulars:

Name in full: _____

MCR number: _____ Specialty: _____

Email address: _____

SUBMISSION INSTRUCTIONS:

(1) Log on at the SMJ website: www.sma.org.sg/cme/smj and select the appropriate set of questions. (2) Select your answers and provide your name, email address and MCR number. Click on "Submit answers" to submit.

RESULTS:

(1) Answers will be published in the SMJ April 2008 issue. (2) The MCR numbers of successful candidates will be posted online at www.sma.org.sg/cme/smj by 15 April 2008. (3) All online submissions will receive an automatic email acknowledgment. (4) Passing mark is 60%. No mark will be deducted for incorrect answers. (5) The SMJ editorial office will submit the list of successful candidates to the Singapore Medical Council.

Deadline for submission: (February 2008 SMJ3B CME programme): 12 noon, 25 March 2008